

Hepatotoxicity of *Cassia fistula* extracts in experimental chicks and assessment of clinical parameters

Irfana Iqbal¹, Mohammad Afzal², Muhammad N. Aftab^{3,*}, Farkhanda Manzoor¹, Afshan Kaleem⁴, Ahmad Kaleem⁵

¹Dept. of Zoology, Lahore College for Women University, Lahore, Pakistan

²Dept. of Biological Science, University of Kuwait, Kuwait.

³Institute of Industrial Biotechnology, GC University, Lahore, Pakistan

⁴Dept. of Biotechnology, Lahore College for Women University, Lahore, Pakistan

⁵Dept. of Surgery, King Edward Medical University, Lahore, Pakistan

*Corresponding author: nauman535@yahoo.com

Abstract

Cassia fistula (Fabaceae) is one of the most commonly used medicinal plants for its antimalarial and antimicrobial activities. So far, safety of the plant fruit seed as a traditional medicine has not been well investigated. Therefore, the effect of *C. fistula* seeds on sub-chronic hepatic toxicity in chicks fed with 30-50 mg/kg methanolic extract of the fruit seeds, for 7-21 days, was investigated. The protective effect of *C. fistula* on organs and the hematological and biochemical parameters were examined. At 40 mg/kg dose of *C. fistula* to chicks showed a non-significant decrease in count of RBCs and other serological values, presumably through a provoked hemolysis of RBCs and/or toxicity of the plant. However, a significant reduction in liver function enzymes (ALP, ALT and AST) urea, and creatinine levels with an increase in plasma protein reflected on its hepato-renal protection. Only nominal pathological lesions were observed in microscopic examination of the chick's hepatic tissues. We propose that *C. fistula* fruit seeds are hepatoprotective and renoprotective.

Keywords: *Cassia fistula*; hepatoprotective; medicinal plant; renoprotective; serological.

1. Introduction

In many countries, *Cassia fistula* Linn (Caesalpinaceae), also known as golden shower tree, is commonly used to treat a number of ailments. In South Asia, the plant is also known as Amaltas meaning 'disease remover'. The parts of the plant are commonly used as a traditional medicine and Ayurvedic medicine for its numerous pharmacological activities. It has been used by native population of Tanzania, Zimbabwe, Mozambique and Brazil for treating malaria (Abid *et al.*, 2014; Grace *et al.*, 2012; Kalaiyarasi *et al.*, 2015). In Sri Lankan traditional medicine, *C. fistula* is used as a cardioprotective and hepatoprotective drug containing antiradical and antioxidant components (Pradeep *et al.*, 2005; El-Nahas *et al.*, 2014; Pradeep *et al.*, 2010; Pradeep *et al.*, 2007; Munasinghe *et al.*, 2001). In Indo-Pak sub-continent, it is known for its antimicrobial, antipyretic and analgesic activities (Panda *et al.*, 2011; Patel *et al.*, 1965; Perumal *et al.*, 1998). Its leaf extract is ovicidal and a repellent

against *Aedes aegypti* and *Callosobruchus maculatus* Fab. (Govindarajan, 2009; Govindarajan *et al.*, 2008; Raja *et al.*, 2000) and its aqueous extract carries antifertility activity in female rats (Yadav & Jain, 1999). The plant is also used as an antacid, for skin eruptions, constipation, baldness, piles, rheumatoid arthritis and amenorrhea. A trypsin inhibitor has been reported from the water extract of *C. fistula* seeds and wound-healing potential of *C. fistula* in albino rats has been reported (Senthil Kumar *et al.*, 2006).

In its phytochemical analysis, phytol, lutein and a di-linolylgalactopyranosyl-glycerol have been identified in *C. fistula* (Grace *et al.*, 2012). In addition, a bioactive flavone glycoside 5,3',4'-trihydroxy-6-methoxy-7-O-alpha-L-rhamnopyranosyl-(1-2)-O-beta-D-galactopyranoside and biochanin A, an isoflavone with antiparasitic activity have been identified in *C. fistula* (Sartorelli *et al.*, 2007a; Yadav & Jain, 1999). Recently, two bioactive compounds benzyl 2-hydroxy-3,6-dimethoxybenzoate and its dimer

dibenzyl 2,2'-dihydroxy-3,6,3'',6''-tetramethoxy-biphenyl-1,1'-dicarboxylate, active against *Cladosporium cladosporioides* and *C. sphaerospermum* have also been identified from *C. fistula* (Sartorelli *et al.*, 2012). Many developing countries suffer with transmissible leishmaniasis and more than 12 million cases have been reported worldwide. *C. fistula* has been reported to contain antileishmanial sterol identified as clerosterol, which is 3.6 times less toxic than pentamidine (pentostam), a recommended drug used in the treatment of leishmaniasis (Sartorelli *et al.*, 2007b). Parts of the plant are also used as livestock feed additive (Makkar *et al.*, 2007). Fruit of the plant is rich in vitamin K, vitamin C, calcium and minerals such as iron and magnesium. For this reason, fruit is used as a mix for chick feed in poultry industry in Pakistan. In the present study, we investigate *C. fistula* for its hepato- and renotoxicity, using chicks as model animals.

2. Materials and methods

Mature *C. fistula* fruits were collected during June-July, 2014, from trees present on campus of Government College University, Lahore, Pakistan. Soaking of the fruit in water and removal of the seeds from the legumes was carried out manually. The seeds were thoroughly washed with water to remove any trace of adhering pericarp. The seeds were later air-dried at room temperature and powdered with the help of a kitchen blender. 100 g of seeds were Soxhlet extracted with methanol for 2 h and the solvent from the extract was removed on a rotavapor to yield 10.3 g (10.3% yield) of the methanol-soluble brown sticky material. An aqueous solution of this material was used to make different concentration of solutions, for feeding the animals.

2.1. Test animals and their treatment

Five week old chicks (*Gallus domesticus*) were purchased from the local market, vaccinated, housed in cages at $30 \pm 2^\circ\text{C}$ and 40% relative humidity with 12 h light/dark regime with an access to water *ad libitum*. Chicks were provided homemade feed consisting of corn, wheat, hulled barley, sunflower seeds, peanuts, wheat bran, split peas and lentils, mixed in equal amounts. After one week of acclimatization, the chicks (180 g-200 g) were randomly assigned to four groups A-D with five animals in each group. The group A, control, orally received a placebo (0.5 ml of normal saline), while test groups B-D, were caged (5 animals each) and orally fed with plant extract redissolved in normal saline at a dose of 30, 40, 50 mg kg⁻¹ body weight for 7, 14 and 21 days. During

experimental periods, all animals had access to feed and water *ad libitum*. At the end of each experimental period, blood was collected from the jugular vein of the chicks in EDTA-coated vacutainers. The tubes were spun in a microfuge and plasma was collected. Serum was collected in tubes without EDTA after letting the blood to clot for 30-60 min followed by centrifugation. Plasma and serum were either used fresh or stored at -20°C until used.

2.2. Total plasma protein assay

Total plasma proteins were measured spectrophotometrically using biuret assay, which offers enhanced sensitivity and avoids interference from colored plant pigments and other substances. Bovine serum albumin was used as a standard (Reichardt *et al.*, 1991).

2.3. Total cholesterol and other bioassays

Cholesterol was assayed calorimetrically as described in the literature (Saha *et al.*, 2013). Urea was assayed by commercially available enzymatic kit (UV GLDH-method; Randox Laboratories Ltd., UK) as described in the literature (Quraishi *et al.*, 2013). Creatinine was assayed by Syal method using alkaline picrate reagent (Syal *et al.*, 2013). Bilirubin was assayed by the method described by Ponghong *et al.* (2011). In this assay, diazotized sulfanilic acid in the presence of n-octyl-beta-d-thioglucoside (OTG) as a solubilizing agent, reacts with bilirubin to form OTG-azobilirubin and measured spectrophotometrically. Alkaline phosphatase (ALP), aspartate amino transferase (AST), and alanine aminotransferase (ALT) were determined by standard kits supplied by Shangai Biotech (Biovision) Co. China. Assay procedure was followed as per manufacturer's instructions. All serological values are shown in Tables 1 and 2.

2.4. Sample preparation for microscopic study

Thin tissue sections prepared by microtome and tissue histology were studied after staining with haematoxylin and eosin stain.

3. Results and discussion

Effect of methanolic extract of *C. fistula* on the blood physiology of chicks was studied. Most parameters studied remained constant, when animals were fed with 30 mg/kg or 40 mg/kg. However, after 50 mg/kg was administered for 3 weeks, most of the biochemical and histological parameters such as mean corpuscular volume (MCH), red blood cells (RBCs), white blood cells (WBCs)

and mean corpuscular hemoglobin (MCH), RBCs, WBCs showed visible deviations from the normal level. It was observed that in total leucocytes count (TLC), differential leukocytes count (DLC) showed a significant decrease ($p < 0.05$) in comparison to the control group. There was also a significant ($p < 0.03$) decrease in proteins, urea and creatinine. However at dosage of 30 mg/kg and 40 mg/kg administered for 3 weeks, did not show any significant change in the blood physiology of chicks as compared to control groups. The data suggested that plant extract impaired hematological and biochemical parameters with mutilation of immune system at 50 mg/kg dose for three weeks of treatment. This presumably reflected on RBCs haemolysis at increased dose of the plant extract, resulting in decreased hematoprotection. Hematological changes in chicks exposed to hypercapnia have been previously reported (Mueller *et al.*, 2013).

Table 1. Measurement of Hematological parameters i.e. RBCs, WBCs, Eosinophil, Lymphocytes, Neutrophils, Hematocrit, Monocytes, MCH, Hb, MCV and MCHC.

Hematological parameter	Control Normal saline	Treated 50mg/kg/body wt.
Total RBCs in $10^6/\text{mm}^3$ or μl		
1 week	4.833 ^b ±0.37	4.88 ^d ±0.10
2 week	5.23 ^a ±0.11	4.88 ^d ±0.10
3 week	5.56 ^a ±0.50	3.3 ^d ±0.28
Total WBCs x $10^3/\text{mm}^3$		
1 week	26.33 ^b ±0.72	24.443 ^d ±0.48
2 week	26.900 ^b ±0.88	23.206 ^d ±1.71
3 week	26.530 ^b ±1.35	21.130 ^d ±0.80
Eosinophil		
1 week	2.5667 ^c ±0.92	1.399 ^d ±0.15
2 week	2.371 ^c ±0.65	1.254 ^d ±0.15
3 week	3.371 ^b ±0.00	1.179 ^d ±0.05
Lymphocytes		
1 week	69.080 ^b ±1.53	62.970 ^d ±3.48
2 week	69.92 ^b ±1.54	62.569 ^d ±1.70
3 week	69.55 ^b ±1.30	60.995 ^d ±1.91
Mean Neutrophils %		
1 week	7.793 ^c ±2.20	4.123 ^d ±0.13
2 week	6.983 ^c ±2.21	3.40 ^d ±0.95
3 week	7.766 ^b ±2.59	3.476 ^d ±0.97
Hematocrit %		
1 week	37.3 ^c ±1.52	32.6 ^d ±1.52
2 week	39.0 ^a ±1.00	31.66 ^d ±2.08
3 week	38.66 ^b ±1.52	30.3 ^c ±1.52
Monocytes %		
1 week	3.53 ^b ±0.92	1.520 ^d ±0.39
2 week	3.336 ^b ±0.86	0.813 ^d ±0.30
3 week	3.683 ^b ±0.85	1.033 ^d ±0.45

Total MCH in pg/cell		
1 week	24.00 ^c ±1.50	21.583 ^d ±0.50
2 week	23.930 ^c ±5.24	20.533 ^d ±1.62
3 week	25.196 ^a ±0.36	18.0 ^d ±2.61
Total Hb in g/dl		
1 week	8.732 ^b ±0.84	7.270 ^d ±0.15
2 week	8.7233 ^c ±0.84	6.96 ^d ±0.31
3 week	10.076 ^b ±0.17	6.0667 ^d ±0.75
Total MCV pg / cell		
1 week	94.253 ^c ±0.67	91.33 ^d ±0.57
2 week	94.623 ^b ±0.83	90.33 ^d ±2.08
3 week	94.5233 ^b ±0.72	89.666 ^d ±1.15
Total MCHC		
1 week	28.233 ^b ±1.15	25.60 ^d ±1.75
2 week	29.233 ^c ±1.15	23.167 ^d ±3.32
3 week	29.073 ^a ±1.0	23.266 ^d ±2.58

Note: Red blood cells (RBCs); White blood cells (WBCs); Mean corpuscular hemoglobin (MCH); Hemoglobin (Hb); Mean corpuscular volume (MCV); Mean corpuscular hemoglobin concentration (MCHC). The alphabets differ significantly at $p \leq 0.05$ level.

Serum hepatic enzymes (ALT, AST ALP) indicative of hepatic fitness in the animals were all significantly reduced ($p < 0.001$) indicating hepatoprotection at 50 mg/kg dose, compared with the control group (Ali *et al.*, 2013; Chakraborty *et al.*, 2007; Saoudi *et al.*, 2011). A non-significant decrease in cholesterol level parallel with a significant ($p < 0.04$) decrease in blood urea in group D animals was observed, indicating potential therapeutic value of the plant. The decrease in serum cholesterol may be due to inhibition of key enzyme 3-hydroxy-3-methylglutaryl CoA reductase (HMGCoR), which is a regulatory step in the synthesis of cholesterol (Parker *et al.*, 2013). An inhibition of lipid biosynthesis and stimulation of lipolysis may have been triggered by flavonoid/anthocyanin type of molecules present in the methanolic extract of the plant (Chang *et al.*, 2013; Parker *et al.*, 2013). The decrease in blood urea may be due to a significant ($p < 0.05$) decrease in serum proteins. The highly significant decrease in creatinine in group-D animals was indicative of liver-kidney protective function of the plant extract. A decrease in total cholesterol rate with an increase in HDL cholesterol level and a decrease in hepatic enzymes (AST, ALT, APL), creatinine, albumin and urea are indicative of liver-kidney protective function of the plant extract (El-Nahas *et al.*, 2014; Hamden *et al.*, 2013; Kalantari *et al.*, 2011; Pradeep *et al.*, 2010). These characteristics make the plant a potentially strong candidate for medicinal application as a pharmaceutical agent for the treatment of liver-kidney dysfunctions, such as hepatitis B and C currently prevalent in South Asian countries.

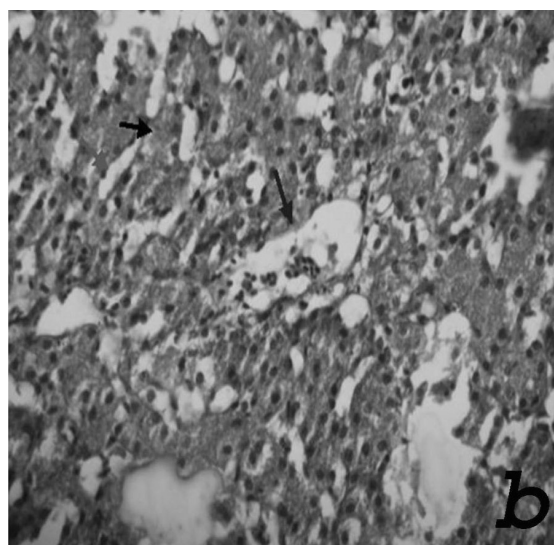
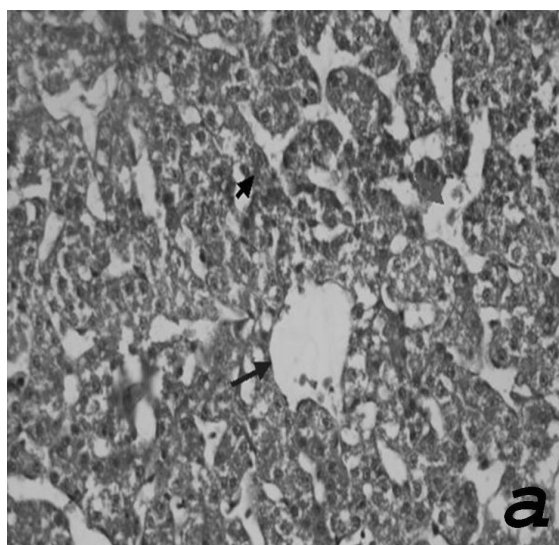
Table 2. Measurement of hepatic enzymes (ALT and AST), Total Cholesterol, Protein, Urea and Creatinine.

Serological Parameters	Control	Treated
	Normal saline	50 mg/kg/body wt.
ALT Concentration in U/l		
1 week	23.83 ^a ±0.15	20.78 ^d ±1.02
2 week	23.55 ^b ±0.51	19.07 ^d ±4.34
3 week	23.49 ^a ±0.06	20.73 ^d ±0.43
AST Concentration in U/l		
1 week	17.28 ^b ±0.60	15.34 ^d ±1.06
2 week	18.43 ^b ±0.11	14.89 ^d ±0.93
3 week	18.57 ^b ±0.85	15.57 ^d ±0.53
Cholesterol Concentration in mg/dl		
1 week	141.91 ^b ±1.92	136.00 ^d ±0.60
2 week	142.19 ^a ±0.87	135.87 ^d ±0.92
3 week	140.38 ^a ±1.48	135.57 ^d ±0.87
Total Protein Concentration in g/l		
1 week	2.84 ^a ±0.45	1.48 ^d ±0.43
2 week	2.97 ^b ±0.2	1.39 ^d ±0.22
3 week	3.11 ^b ±0.75	1.50 ^d ±0.36
Total Urea Concentration in mmol/l		
1 week	8.89 ^a ±1.15	5.87 ^d ±0.47
2 week	10.03 ^b ±0.69	5.15 ^d ±0.23
3 week	9.30 ^b ±0.90	6.03 ^d ±0.40
Total Creatinine Concentration in mg/dl		
1 week	7.95 ^a ±1.54	3.35 ^d ±0.46
2 week	7.16 ^b ±0.94	3.40 ^d ±0.54
3 week	6.81 ^b ±1.18	2.94 ^d ±0.76

Note: Alanine Aminotransferase concentration (ALAT); Aspartate Aminotransferase (ASAT). The alphabets differ significantly at $p \leq 0.05$ level.

The hematological and biochemical data was further supported by histopathological studies of the liver. The normal liver histology showed a homogeneous mass of polygonal hepatocytes with a prominent centrally located nucleus. Hepatic sinusoids were also observed with a prominent and normal structure of the bile duct. Hepatic artery with narrow lumen and veins with comparatively broader lumen were recognizable. The melanomacrophage centers were also prominent in the vicinity of arteries and the bile duct.

The group 'B' animals treated with 30 mg/kg of seed extract for 21 days showed slight vacuolation, while animals in group 'C' treated with 40 mg/kg/bodyweight of seed extract for 21 days showed an increase in the cellular diameter due to hypertrophy. The nuclei were pyknotic, in some areas; lesions leading to slight necrosis and cellular infiltrations was also seen. While the animals in Group 'D' treated with 50 mg/kg of seed extract for 21 days showed no significant changes in the structural make up of liver tissue, which supports lower to normal levels of hepatic enzymes in serum indicative of hepato-protective nature of the plant extract.



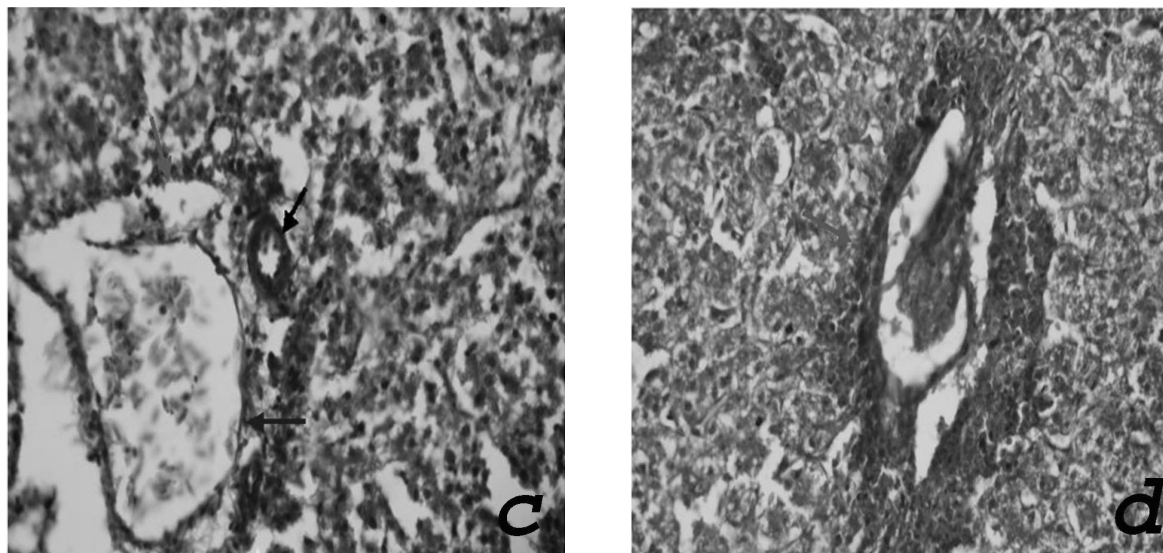


Fig.1. (a) Photomicrograph of control groups (40x H & E), liver with normal cords of hepatocytes (small arrows), central vein (blue arrow) and sinusoids (red arrow). (b) Photomicrograph after one week (40x H & E), liver with normal cords of hepatocytes (small arrows), central vein (blue arrow) and sinusoids (red arrow). (c) Photomicrograph after two weeks (40x H & E), liver with normal codes of hepatocytes and portal triade with vein containing RBC (blue), bile duct (black arrow) and artery (red arrow). (d) Photomicrograph after three weeks (40x H & E), liver with necrosis of hepatocytes around portal triade (red arrow).

4. Conclusion

C. fistula methanolic extract has slight serological implications with hepatoprotective and renal protective characteristics. The plant can thus be safely used as a herbal medicine and also as a feed additive for chicks. These data suggest that further studies should be performed for better understanding of the mechanism of the chemo-preventive efficacy of *C. fistula*.

5. Acknowledgement

The author is thankful to the Department of Zoology, GC University (II) Lahore, Pakistan for providing research facilities and encouragement during the course of this study.

References

- Abid, R., Mahmood, R., Rajesh, K.P. & Kumara, S.B.E. (2014). Potential in vitro antioxidant and protective effect of *Cassia fistula* Linn.fruit extracts against induced oxidative damage in human erythrocytes. *International Journal of Pharmaceutical Science*, **6**(9):497-505.
- Ali, G., Liu, Q., Hua, W. & Huang Wang, D. (2013). Hepatoprotective evaluation of the total flavonoids extracted from flowers of *Abelmoschus manihot* (L.) Medic: In vitro and in vivo studies. *Journal of Ethnopharmacology*, **146**(3):794-802.
- Chakraborty, T., Bhuniya, D., Chatterjee, M., Rahaman, M. & Singha, D. (2007). *Acanthus ilicifolius* plant extract prevents DNA alterations in a transplantable Ehrlich ascites carcinoma-bearing murine model. *World Journal of Gastroenterology*, **13**(48):6538-6548.
- Chang, J.J., Hsu, M.J., Huang, H.P., Chung, D.J. & Chang, Y.C. *et al.* (2013). Mulberry anthocyanins inhibit oleic acid induced lipid

accumulation by reduction of lipogenesis and promotion of hepatic lipid clearance. *Journal of Agriculture and Food Chemistry*, **61**(25): 6069-6076.

El-Nahas, Salwa, K.E.N., Afaf, A.A.H., Ahmad, M.A.H. & Heba, A.A.R. (2014). Effect of methanol extract of three dietary plants growing in Egypt on mice fed with high fat diet. *European Review for Medical and Pharmacological Sciences*, **4**(3):104-111.

Govindarajan, M. (2009). Bioefficacy of *Cassia fistula* Linn. (Leguminosae) leaf extract against chikungunya vector, *Aedes aegypti* (Diptera: Culicidae). *European Review for Medical and Pharmacological Sciences*, **13**(2):99-103.

Govindarajan, M., Jebanesan, A. & Pushpanathan, T. (2008). Larvicidal and ovicidal activity of *Cassia fistula* Linn.leaf extract against filarial and malarial vector mosquitoes. *Parasitology Research*, **102**(2):289-292.

Grace, M.H., Lategan, C., Graziose, R., Smith, P.J. & Raskin, I. *et al.* (2012). Antiplasmodial activity of the ethnobotanical plant *Cassia fistula*. *Natural Product Communications*, **7**(10):1263-1266.

Hamden, K., Mnafigui, K., Amri, Z., Aloulou, A. & Elfeki A. (2013). Inhibition of key digestive enzymes related to diabetes and hyperlipidemia and protection of liver-kidney functions by trigonelline in diabetic rats. *Scientia Pharmaceutica*, **81**(1):233-246.

Kalaiyarasia, C., Kalivaradhan, K. & Govindharaj, R. (2015). Anticonvulsant and anxiolytic activities of ethyl acetate fraction of *Cassia fistula* Linn.pods in mice. *Pharmacognosy Communication*, **5**(1):76-82.

Kalantari, H., Jalali, M., Jalali, A., Mahdavinia, M. & Salimi, A. *et al.* (2011). Protective effect of *Cassia fistula* fruit extract against bromobenzene-induced liver injury in mice. *Human & Experimental Toxicology*, **30**(10):1039-1044.

Makkar, H.P., Francis, G. & Becker, K. (2007). Bioactivity of phytochemicals in some lesser-known plants and their effects and potential applications in livestock and aquaculture production systems. *Animal: An International Journal of Animal Bioscience*, **1**(9):1371-1391.

- Mueller, C.A., Tazawa, H. & Burggren, W.W. (2013).** Dynamics of metabolic compensation and hematological changes in chicken (*Gallus gallus*) embryos exposed to hypercapnia with varying oxygen. *Respiratory Physiology and Neurobiology*, **185**(10): 272-280.
- Panda, S.K., Padhi, L.P. & Mohanty, G. (2011).** Antibacterial activities and phytochemical analysis of *Cassia fistula* (Linn.) leaf. *Journal of Advanced Pharmaceutical Technology and Research*, **2**(1):62-67.
- Parker, R.A., Garcia, R.A., Ryan, C.S., Liu, X. & Shipkova, P. et al. (2013).** Bile Acid and Sterol Metabolism with Combined HMG CoA Reductase and PCSK9 Suppression. *Journal of Lipid Research*, **54**(9):2400-9.
- Patel, D.G., Karbhari, S.S., Gulati, O.D. & Gokhale, S.D. (1965).** Antipyretic and analgesic activities of *Aconitum spicatum* and *Cassia fistula*. *Archives Internationales De Pharmacodynamie Et De Therapie*, **157**(1):22-27.
- Perumal, Samy, R., Ignacimuthu, S. & Sen, A. (1998).** Screening of 34 Indian medicinal plants for antibacterial properties. *Journal of Ethnopharmacology*, **62**(2):173-182.
- Ponhong, K., Teshima, N., Grudpan, K., Motomizu, S. & Sakai, T. (2011).** Simultaneous injection effective mixing analysis system for the determination of direct bilirubin in urinary samples. *Talanta*, **87**(1):113-117.
- Pradeep, K., Mohan, C.V., Anand, K.G. & Karthikeyan, S. (2005).** Effect of pretreatment of *Cassia fistula* Linn. leaf extract against subacute CCl₄ induced hepatotoxicity in rats. *Indian journal of Experimental Biology*, **43**(6): 526-530.
- Pradeep, K., Mohan, C.V., Gobianand, K. & Karthikeyan, S. (2007).** Effect of *Cassia fistula* Linn. leaf extract on diethylnitrosamine induced hepatic injury in rats. *Chemico-Biological Interactions*, **167**(1):12-18.
- Pradeep, K., Raj, Mohan, C.V., Gobianand, K. & Karthikeyan, S. (2010).** Protective effect of *Cassia fistula* Linn. on diethylnitrosamine induced hepatocellular damage and oxidative stress in ethanol pretreated rats. *Biological Research*, **43**(1):526-530.
- Quraishi, R., Lakshmy, R., Mukhopadhyay, A.K. & Jaiikhani, B.L. (2013).** Analysis of the stability of urea in dried blood spots collected and stored on filter paper. *Annals of Laboratory Medicine*, **33**(3):190-192.
- Raja, N., Albert, S. & Ignacimuthu, S. (2000).** Effect of solvent residues of *Vitexnegundo* Linn. and *Cassia fistula* Linn. on pulse beetle, *Callosobruchus maculatus* Fab. and its larval parasitoid, *Dinarmus vagabundus* (Timberlake). *Indian Journal of Experimental Biology*, **38**(3):290-292.
- Reichardt, W. & Eckert, W. (1991).** The determination of protein content of milk, cheese, and meat with the use of the biuret reaction. *Die Nahrung*, **35**(7):731-738.
- Saha, S.K., Das, S.C., Abdullah, A.I.E., Sarker, M. & Uddin, M.A. et al. (2013).** Biochemical alterations and liver toxicity analysis with pioglitazone in healthy subjects. *Drug and Chemical Toxicology*, **36**(2): 149-154.
- Saoudi, M., Jebahi, S., Jamoussi, K., Ben. & Salah, G. et al. (2011).** Haematological and biochemical toxicity induced by methanol in rats: ameliorative effects of *Opuntia vulgaris* fruit extract. *Human and Experimental Toxicology*, **30**(8): 1963-1971.
- Sartorelli, P., Andrade, S.P., Melhem, M.S., Prado, F.O. & Tempone, A.G. (2007a).** Isolation of anti leishmanial sterol from the fruits of *Cassia fistula* using bioguided fractionation. *Phytotherapy Research: PTR*, **21**(7):644-647.
- Sartorelli, P., Carvalho, C.S., Reimao, J.Q., Ferreira, M.J. & Tempone, A.G. (2007b).** Antiparasitic activity of biochanin A, an isolated isoflavone from fruits of *Cassia fistula* (Leguminosae). *Parasitology Research*, **104**(2):311-314.
- Sartorelli, P., Lago, J.H., Cunha, R.L., Kitamura, R.O. & Young, M.C. (2012).** A new minor dimmeric ester from seeds of *Cassia fistula* L. (Leguminosae). *Natural Product Research*, **26**(2):36-41.
- Syal, K., Srinivasan, A. & Banerjee, D. (2013).** Streptomycin interference in Jaffe reaction – possible false positive creatinine estimation in excessive dose exposure. *Clinical Biochemistry*, **46**(1-2):177-179.
- Senthil, Kumar, M., Sripriya, R., Vijaya, R.H. & Sehgal, P.K. (2006).** Wound healing potential of *Cassia fistula* on infected albino rat model. *The Journal of Surgical Research*, **131**(2):283-289.
- Munasinghe, T.C.J., M., Seneviratne, C.K., Thabrew, M.I. & Abeysekera, A.M. (2001).** Antiradical and antilipoperoxidative effects of some plant extracts used by Sri Lankan traditional medical practitioners for cardio protection. *Phytotherapy Research: PTR*, **15**(6):519-523.
- Yadav, R. & Jain, G.C. (1999).** Antifertility effect of aqueous extract of seeds of *Cassia fistula* in female rats. *Advances in Contraception: The Official Journal of the Society for the Advancement of Contraception*, **15**(4):293-301.

Submitted : 03/03/2016

Revised : 29/03/2016

Accepted : 31/03/2016

التسمم الكبدي لمستخلص الناسور كاسيا في كتاكت التجارب وتقييم العوامل الطبية

¹ارفانا اقبال، ²محمد أفضل، ³محمد أفتاب، ¹فرخنده منظور، ⁴أفشان كاليم، ⁵أحمد كاليم

¹قسم علم الحيوان - كلية لاهور جامعة النساء - لاهور - باكستان

²قسم العلوم البيولوجية - جامعة الكويت - الكويت

³معهد التكنولوجيا الحيوية الصناعية GC - لاهور - باكستان

⁴قسم التكنولوجيا الحيوية - كلية لاهور جامعة النساء - لاهور - باكستان

⁵قسم الجراحة - جامعة الملك إدوارد الطبية - لاهور - باكستان

المراسلة مع المؤلف: البريد الإلكتروني nauman535@yahoo.com

الملخص العربي

خيار شمبر (الفصيلة البقولية) هو واحد من النباتات الطبية الأكثر شيوعاً عن الأدوية المضادة للملاريا والأنشطة المضادة للجراثيم. وحتى الآن، السلامة من بذور ثمرة النبات كدواء تقليدي لم يتم التحقيق فيها بشكل جيد. ولذلك، فإن تأثير بذور جيم الناسور على السمية الكبدية شبه المزمدة في فراخ تتغذى على 30-50 ملغ / كغ من المستخلص المثلي من بذور الفاكهة، لمدة 7-21 يوماً تم دراسته. تم فحص التأثير الوقائي لناسور كاسيا على أعضاء والقياسات الدموية والبيوكيميائية. أظهرت جرعة مقدارها 40 ملغم / كغم من ناسور كاسيا أعطيت إلى الدجاج انخفاضاً غير ملحوظ في عدد كرات الدم الحمراء والقيم المصلية الأخرى، ويفترض أن يكون ذلك من خلال تنشيط تكسير كرات الدم الحمراء / أو سمية النبات. ومع ذلك، لوحظ انخفاض كبير في إنزيمات ووظائف الكبد (ALT، ALP وAST) واليوريا، ومستويات الكرياتينين مع زيادة في بروتين البلازما مما يعكس قدرته على الحماية الكبدية والكلى. وقد لوحظ وجود بعض الأضرار المرضية في الفحص المجهرى في الأنسجة الكبدية للفراخ. نقترح أن بذور ثمرة جيم الناسور لها تأثير واقٍ على الكبد والكلى.